



University of
CINCINNATI

Emergency Medicine



ANNALS OF B POD

Winter 2021 (Volume XIV Issue II)



Leadership

Excellence

Opportunity

Editors

Adam Gottula, MD
Simanjit Mand, MD
James Makinen, MD
Meaghan Frederick, MD
Colleen Laurence, MD
Emily Roblee, MD
Arthur Broadstock, MD
Jonathan Chuko, MD
Laura Frankenfled, MD
Kristin Meigh, MD

Faculty Editors

William Knight, MD
Natalie Kreitzer, MD
Robbie Paulsen, MD
Ryan LaFollette, MD
Kari Gorder, MD
Grace Lagasse, MD
Jessica Baez, MD

Founding Editors

Aaron Bernard, MD
Christopher Miller, MD



3

**Epididymitis to
pyocele**

Laura Frankenfled, MD



4

Molar Pregnancy

Meaghan Frederick, MD



6

**Lymphogranuloma
venereum**

Jonathan Chuko, MD



8

Retzius abscess

Kristin Meigh, MD



12

**Summer Penile
Syndrome**

Laura Frankenfled, MD

Getting the ball rolling on epididymitis:

Progression to pyocele



Laura Frankenfeld
University of Cincinnati R2

History of Present Illness

A male in his 70s presents with eight days of worsening left-sided testicular pain and swelling. He states that the pain had been gradually worsening to the point that he is unable to sit upright. He denies fever, dysuria, hematuria, urinary frequency, penile discharge, or preceding trauma to the groin. He has no reported or documented history of genitourinary instrumentation. The patient is sexually active with one female partner and does not use barrier protection.

Chart review reveal that the patient was evaluated in the emergency department eight days prior upon symptom onset for similar complaints. His blood work at that time showed a leukocytosis of 24,000 and a urine sample during this visit revealed >100 white blood cells per high powered field on microscopy. Urine culture speciated *Streptococcus agalactiae*. The patient was diagnosed with epididymitis and was prescribed a course of Bactrim before being discharged back to his living facility. Discussion with the nursing facility revealed that the patient refused antibiotics upon his return for unknown reasons.

Past Medical History

Benign prostatic hyperplasia
Hypertension
Schizophrenia

Past Surgical History

None reported

Medications

Amlodipine
Atorvastatin
Benzotropine
Lisinopril
Propranolol
Quetiapine
Tamsulosin

Allergies

No known drug allergies

Physical Exam



T: 98.4 °F



HR: 65



BP: 134/82



RR: 24



SpO2: 100% on RA

The patient is a well-appearing African American male lying in bed and in no acute distress. His mucous membranes are moist. He has an unremarkable cardiopulmonary exam. Abdominal exam-

ination is notable for focal left lower quadrant tenderness without rigidity, rebound, or guarding. The patient's genitourinary exam reveals a swollen, warm, and diffusely tender left testicle that does not transilluminate. He has a negative cremasteric reflex and a negative Prehn sign. There is no evidence of tenderness, erythema, edema, or crepitus in the perineal region.

Diagnostic Tests

14.7			
11.2	176	131	105
42.9		9	
		4.6	19
		0.84	---

UA: Notable only for trace urobilinogen

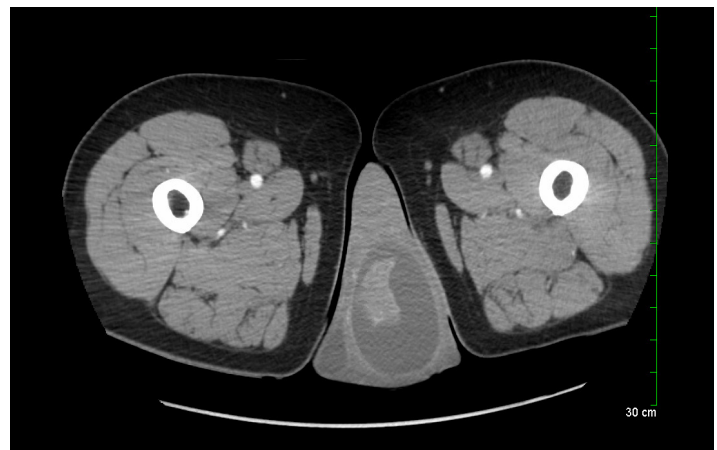

Image 1: CT abdomen and pelvis with IV contrast showing scrotal edema and left hydrocele exerting mass effect on the testicle, consistent with epididymo-orchitis and pyocele.

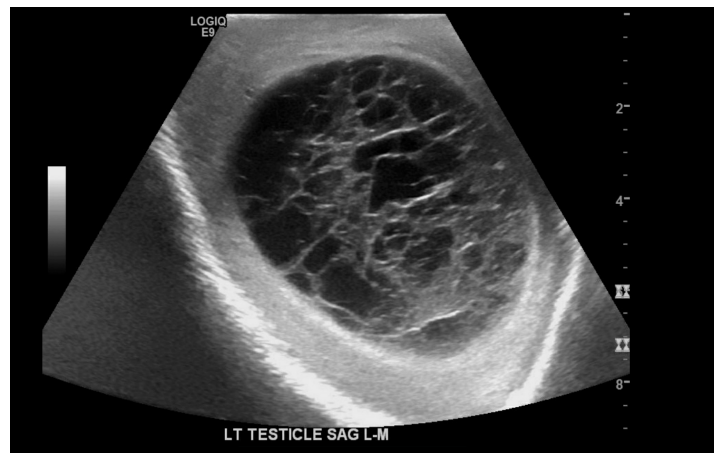


Image 2: Representative image of patient's testicular ultrasound showing a large complex hydrocele consistent with a pyocele.

Progression to pyocele

Continued on page 14



Molar Pregnancy & Thyrotoxicosis

Meaghan Frederick, MD
University of Cincinnati R3

History of Present Illness

The patient is a female in her 20s, G1P0 at eight weeks and six days gestation by last menstrual period, with a pregnancy of unknown location, who presents to the emergency department after being found to be hypertensive and tachycardic at her obstetrics clinic appointment. She is being evaluated by her obstetrician for two weeks of vaginal bleeding. The patient endorses initial heavy bleeding with passage of clots that had improved and now approximates her bleeding amount like that of her previous menses. The vaginal bleeding is associated with nausea and lower abdominal cramping.

Past Medical History

None

Past Surgical History

None

Medications

None

Allergies

Unknown

Physical exam

The patient is a well appearing but slightly anxious. Cardiovascular exam notes tachycardic with a regular rhythm and no murmurs, rubs, or gallops. The abdominal exam is significant for right lower quadrant, suprapubic, and periumbilical tenderness without rebound or guarding. The patient's cervix is less than 1 cm dilated, and the vaginal vault contained dark red blood. The patient's physical exam is otherwise unremarkable.



T: 98°F



HR: 150



BP: 155/74

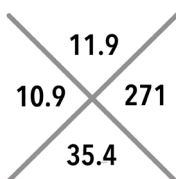


RR: 16



SpO2: 96% on RA

Diagnostics



Beta HCG Quantative: 11,774,500
T+S: O-positive
BMP: Within normal limits
LFTs: Within normal limits

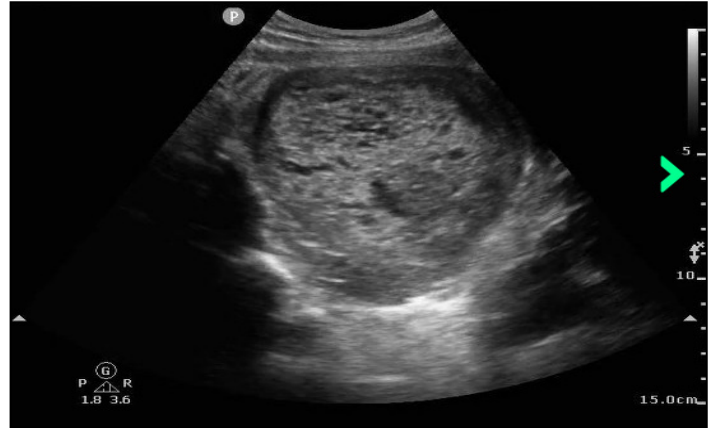

Image 3: Representative transabdominal ultrasound image of a molar pregnancy

Hospital Course

In the emergency department the patient received 2 L of lactated ringers and remained tachycardic with a heart rate in the 110s. Pelvic ultrasound demonstrated an enlarged 14-week gestation uterus with an intrauterine mass concerning for a complete hydatidiform mole. In the setting of a hydatidiform mole and abnormal vital signs, TSH and free T4 were ordered given the concern for hyperthyroidism and impending thyroid storm. The patient was empirically given propranolol 60 mg. Her TSH returned low at <0.02, and her total T3 and free T4 were both elevated at 337 and 2.1 respectively. Obstetrics and Gynecology (OB/GYN) was consulted and the patient was taken directly to the operating room for a stat dilation and curettage (D&C). She underwent an uncomplicated D&C leading to resolution of her tachycardia, hypertension, and vaginal bleeding post-operatively. The patient was discharged home on post-operative day one. As an outpatient, the patient was found to have an abnormal mass in the posterior uterine fundus with persistently detectable human chorionic gonadotropin (hCG) levels concerning for the development of gestational trophoblastic neoplastic disease.

Discussion

Epidemiology and Pathophysiology

Molar pregnancies are a type of gestational trophoblastic disease, in which there is abnormal proliferation of trophoblastic placental tissues. Molar pregnancies are caused by aberrancies in the fertilization process, and the specific abnormality determines whether it will be a complete or partial molar pregnancy. Complete molar pregnancies are most commonly caused by a haploid sperm fertilizing an empty ovum and then duplicating, resulting in 46 XX zygote in which all genetic material is paternal in origin. A more uncommon cause of complete moles occurs in approximately 10% of cases, where two haploid sperm both fertilize an empty ovum and result in 46 XY of solely paternal origin.¹ Com-

plete moles, which contain both maternal and paternal DNA, are extremely rare and are thought to be secondary to defects in imprinting processes and specific genetic mutations. Partial moles are typically triploid, and result from simultaneous fertilization of a normal ovum by two sperm, resulting in a 69 - - - karyotype. Both complete and partial moles contain atypical trophoblastic tissues; however, complete moles rarely contain any fetal tissue, whereas partial moles do.

Molar pregnancies are rare in North America with an incidence estimated at less than 1 per 1000, although frequency varies throughout the world with rates reaching as high as 2 per 1000 in Japan.¹ It is important to recognize that these numbers may underestimate the true incidence due to misdiagnoses. One study demonstrated that 91% of partial molar pregnancies were initially clinically misdiagnosed as spontaneous abortion and were later found to be molar pregnancies.⁶

Risk factors for hydatidiform mole include extremes of maternal age, previous spontaneous abortion, and previous molar pregnancy. Women less than 21 years of age and over 35 years of age have an estimated two-fold increase in risk compared to the general population, and this further increases to seven and a half-fold risk when the mother is greater than 40 years old. Those with a prior spontaneous abortion are at two to three-fold higher risk, and those with a previous molar pregnancy are at 10-20-fold higher risk for recurrence.²⁻⁴

Clinical Presentation

Both partial and complete molar pregnancies frequently present with similar symptoms of a regular pregnancy, including a positive home pregnancy test, missed menstrual cycle, nausea, breast swelling, and lower abdominal pain. Discovery of molar pregnancies without additional symptoms has increased as access to ultrasonography and hCG quantitative tests have improved, leading to earlier diagnosis. When additional symptoms are present, vaginal bleeding is the most common additional symptom associated with molar pregnancies, occurring in the first trimester in 46-90% of cases.^{5,7} Hyperemesis may also be associated with molar pregnancies, often occurring earlier and more severe than in routine pregnancies. Uterine enlargement is found in up to 46% of complete molar pregnancies while partial molar pregnancies have variable enlargement of the uterus.⁸⁻⁹ Overstimulation of the ovaries by high levels of hCG can lead to the development of theca lutein cysts, which are frequently bilateral, in more than 16% of molar pregnancies.⁹

Hyperthyroidism and early onset pre-eclampsia are symptoms that develop later in the course of the disease and are rare given the frequency of first trimester diagnosis and treatment.⁵ The etiology of hyperthyroidism is due to hCG stimulation of the TSH receptor. This requires exceedingly large quantities of hCG as it has significantly less potency at the TSH receptor than TSH.¹⁰ Molar pregnancy induced hyperthyroidism resolves with removal of the molar pregnancy and acute management of molar pregnancy associated thyroid storm follows typical thyroid storm management.

Early onset pre-eclampsia is defined as systolic blood pressure greater than or equal to 140 or diastolic blood pressure greater

than or equal to 90 on at least two occasions and new onset of at least one of the following: proteinuria, thrombocytopenia, creatinine elevation greater than 1.1, transaminitis greater than or equal to two times the upper limit of normal, pulmonary edema, persistent idiopathic headache, or visual symptoms at a gestational age less than 20 weeks. Although the exact etiology of early onset preeclampsia in molar pregnancies is unclear, some studies suggest it may be caused by dysregulation of angiogenic factors.¹¹⁻¹³ Patients with preeclampsia before 20 weeks should be considered to have a molar pregnancy until proven otherwise. Eclampsia and premature eclampsia may also be seen with molar pregnancies, but the incidence is extremely rare.²⁹⁻³⁰

While the above symptoms can be seen in both types of molar pregnancies, uterine enlargement, theca lutein cysts, hypertension, preeclampsia, and hyperthyroidism are significantly less frequent in partial molar pregnancies. The predominant symptom of partial molar pregnancy is vaginal bleeding, as the remainder of the signs and symptoms are driven by hCG, which is produced at notably lower levels when compared to complete molar pregnancies.

Diagnosis

Emergency medicine providers should suspect molar pregnancy clinically based on factors such as hyperemesis and hypertension in early pregnancy prior to ordering and interpreting HCG levels. HCG levels are elevated greater than 100,000 in nearly 50% of complete moles while less than 10% of patients with a partial mole had hCG levels > 100,000.^{6,14-15} While hCG levels exceeding 275,000 may be seen in normal pregnancy, hCG in molar pregnancies is significantly elevated compared to normal pregnancies of the same gestational age. HCG levels are elevated greater than 100,000 in nearly 50% of complete moles while less than 10% of patients with a partial mole had hCG levels > 100,000.^{6,14-15} HCG levels >100,000 should prompt concern for a molar pregnancy especially if a normal intrauterine pregnancy (IUP) is not identified. There have been case reports of coexistent molar and viable pregnancies; therefore, a concerning history with an elevated hCG, in the setting of a confirmed IUP, should prompt repeat evaluation to rule out concomitant molar and viable gestations.¹⁶⁻¹⁸

Ultrasonography is first line imaging modality to evaluate for molar pregnancy. On pelvic ultrasound, complete moles have the textbook 'snowstorm appearance' describing an echogenic intrauterine mass with scattered anechoic cyst-like lesions, and an absence of fetal parts. Other findings that suggest a complete mole are the absence of amniotic fluid, and the presence of ovarian cysts. Partial moles do not have this classic appearance and should instead be suspected when there is a growth restricted fetus, reduced amniotic fluid, or a placenta with cystic or irregular lesions. Unfortunately, studies have demonstrated that while specificity of ultrasound can be as high as 99.8%, the sensitivity can be as low as 20%. The sensitivity of ultrasound for the diagnosis of molar pregnancy is higher in complete moles than in partial moles, and increases with increasing gestational age.¹⁹⁻²² Definitive diagnosis is made on pathology following evacuation.

For pregnancies concerning for molar disease that have an inde-



Lymphogranuloma venereum

Jonathan Chuko, MD
University of Cincinnati R2

History of Present Illness

The patient is a male in his 20s with a history of recurrent skin and soft tissue abscesses of the buttocks and a recent diagnosis of balanitis, who presents to the emergency department with a chief complaint of groin pain. The pain is bilateral, associated with swelling, and had been present for two weeks. The patient has experienced difficulty walking secondary to the pain. The patient denies testicular pain, scrotal swelling, penile discharge, fevers, chills, nausea, or vomiting. He endorses a ten-pound weight loss in the last month with associated night sweats. The patient reports that he participated in unprotected receptive and penetrative oral and anal sex with men. He has no known history of sexually transmitted infections (STI). He has two active sexual partners, both with unknown STI status.

The patient does recall a small, painless ulcerative wound on the glans of his penis one month prior to presentation to the emergency department. He presented to an outside hospital emergency department at that time and was diagnosed with balanitis. After a short course of topical miconazole, cephalexin, and strict perineal hygiene, the lesion resolved.

Past Medical History

- Balanitis
- Perianal abscess
- Left thigh abscess

Past Surgical History

Open reduction, internal fixation of right mandible

Medications

Ibuprofen

Allergies

No known medication allergies

Social History

2 ppd tobacco use, social alcohol consumption

Physical Exam



T: 99.1 °F



HR: 108



BP: 133/76



RR: 16

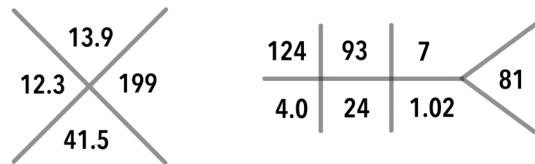


SpO2: 100% on RA

The patient is chronically ill-appearing, disheveled, in no acute distress. Cardiac auscultation is notable for tachycardia without other adventitious sounds. Lungs are clear to auscultation bilaterally. His abdomen is soft, nontender throughout. The genitourinary exam is remarkable for a large area of induration without fluctuance in the left inguinal region measuring 5 cm by 5 cm. The penis is un-

circumsized without lesions, and no discharge at the urethral meatus was noted. There is normal testicular lie without tenderness or masses. The neurological exam is grossly normal. The remainder of the physical exam is unremarkable.

Diagnostics



HIV 1 antibody: reactive

HIV 2 antibody: nonreactive

HIV RNA quant: 185,828 copies/mL

CD4 count: 327

UA: 13 RBC, 6 WBC, rare bacteria, 40 mg/dl ketones, - nitrite, - leukocyte esterase

Chlamydia trachomatis urine DNA: positive

Neisseria gonorrhoeae urine DNA: negative

Syphilis RPR screen: reactive

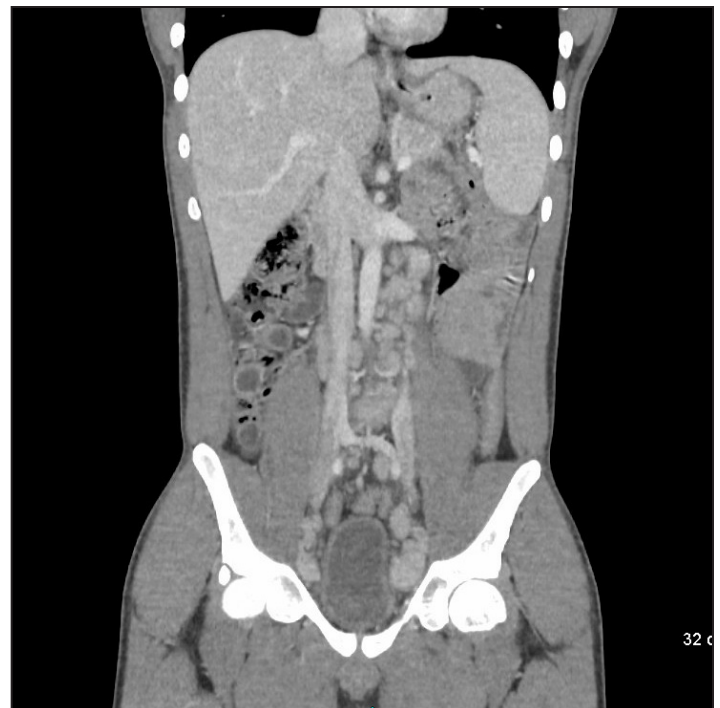


Image 4: CT abdomen and pelvis with IV contrast showing extensive lymphadenopathy involving inguinal, iliac chain, retroperitoneal and retrocrural nodal stations. The largest lymph node in the left superficial inguinal region displays central hypodense areas likely secondary to necrosis. This lymph node measures approximately 4.1 x 2.8 cm in greatest axial dimensions.

Hospital Course

The patient was resuscitated for presumed dehydration given his hyponatremia, hypochloremia and mild tachycardia. Hematology was consulted for evaluation of lymphoma given the extent of the patient's lymphadenopathy and recommended admission to their service for further workup. Upon admission, the patient was found to have a reactive HIV 1 antibody test with a viral load of 185,828 copies/mL and initial CD4 count of 327 cells/mm³. RPR screen and chlamydia trachomatis urine DNA were also positive. On hospital day two, the patient received an inguinal lymph node biopsy by the surgical oncology service, eventually showing extensive granulomatous lymphadenitis with central suppuration and multifocal abscess formation with no overt evidence of lymphoma. Infectious disease established care with the patient, and he was started on antiretroviral medication prior to discharge. Chlamydial infection was treated with 1 g azithromycin and syphilis with 2.4 million units IM penicillin. The patient had an uncomplicated three-day hospital course and was diagnosed with lymphogranuloma venereum.

Discussion

Epidemiology

Chlamydia trachomatis is an obligate intracellular pathogen that targets epithelial cells at various mucosal sites, resulting in a wide range of clinical presentations. Its different serotype can target distinct tissues: A-C causes trachoma, D-K causes anogenital infection, and L responsible for lymphogranuloma venereum (LGV). In the case of LGV, the L1, L2, and L3 serovars cross the epithelial cells of mucous membranes and infect the lymphatics, often after unprotected vaginal, anal, or oral sexual contact. The bacteria travel to regional lymph nodes via the lymphatics and multiply within mononuclear phagocytes. Over a few weeks, lymphangitis becomes more prominent with necrosis and abscess formation within the lymph nodes.⁹

The first clinical case of LGV was defined by Durand, Nicolas, and Favre in 1913.¹ It is endemic to tropical and subtropical areas of the world. In the United States, the incidence is thought to be low. National reporting of LGV ended in 1995, as at that time, it was highly uncommon in the Western world.² Unfortunately, since 2003, there have been multiple LGV outbreaks, notably in the Netherlands and United Kingdom. While LGV can affect all ages, most patients are diagnosed between the ages of 15 and 40, when they are the most sexually active. Most cases identified in Europe and North America involve men who have sex with men (MSM) patients. Upon presentation, a large proportion of these patients will be coinfecting, with up to 80% of patients being HIV positive, and up to 40% presenting with another STI.⁸

Clinical Presentation

The clinical symptoms of LGV are widely variable and classically divided into three stages. The primary stage involves localized inflammation at the site of exposure, where a transient painless papule, erosion, pustule, or ulcer appears after an incubation period of 3-30 days. In males, the most common site of this lesion is the coronal sulcus on the glans of the penis and will usually heal within one week without treatment. At this stage, these lesions are indistinguishable from that of a syphilitic chancre without serologic testing.

During the secondary stage, which emerges weeks to months later, local lymph nodes draining the site of primary infection enlarge, and necrotic areas develop following an inflammatory process. Commonly, this involves the painful inflammation of both the superficial and deep inguinal lymph nodes. It is during this stage that the classic "bubo" or fluctuant masses of LGV arise. These "buboes" will rupture in approximately one-third of patients, with the rest developing indurated masses. On physical exam, these patients may have the "groove sign," a pathognomonic physical exam finding in which linear depressions can be felt at the inguinal ligament separating enlarged inguinal and femoral lymph nodes. In women, backache or pelvic pain is common at this stage with the initial lesions at the cervix or upper vagina.

Finally, the tertiary stage is characterized by a chronic inflammatory response resulting in the formation of fistulas, rectal strictures, and abscesses. Left untreated, this chronic lymphangitis will often lead to persistent edema and sclerosing fibrosis. At this stage, many of the complications require surgical intervention.³

A novel emerging clinical presentation of LGV involves proctitis with symptoms of rectal pain, anorectal bleeding, and hemopurulent rectal discharge. These patients can often undergo extensive workup and even treatment for inflammatory bowel disease before arriving at the true diagnosis. The fact that genital ulcers and inguinal symptoms are less common in these patients further complicates the clinical picture.

Diagnosis

LGV is largely a clinical diagnosis, arrived at through a detailed sexual history, genitourinary physical exam, and appropriate clinical suspicion. The gold standard for chlamydial testing is nucleic acid amplification testing (NAAT). The assays are highly sensitive and specific, but do not allow for serotype identification. Currently, NAAT is only approved by the US Food and Drug Administration (FDA) for genital sites, including urine, cervical, and urethral swabs. Extragenital specimens include anogenital lesion swabs from ulcer base exudate, rectal mucosa swab, and buboes aspirate. While not approved by the FDA, these specimens can be still sent for culture, direct immunofluorescence, or nucleic acid detection to help aid in diagnosis.⁶ At the moment, differentiating LGV from non-LGV *C. trachomatis* entails PCR-based genotyping that is not yet widely available and too slow to effectively change clinical management. Furthermore, LGV serologies are also controversial, as they are hampered by cross reactivity, variability in titers, and variability in the interpretation of titers.⁷ Given these limitations, the combination of an appropriate clinical context and a urine NAAT positive for Chlamydia is the current most practical approach to diagnosing LGV.

Treatment

Patients with clinical suspicion for LGV should be presumptively treated prior to the results of diagnostics. Early administration of antibiotics can cure the infection and can prevent further tissue damage. The recommended antibiotic regimen based on the Center for Disease Control and Prevention's guidelines is doxycycline 100 mg twice daily for 21 days. Pregnant and lactating women should be treated instead

Kristin Meigh, MD
University of Cincinnati R2

History of Present Illness

The patient is a male in his 40s with a past medical history of intravenous drug use (IVDU) who presents to the emergency department with chief complaints of dysuria and inguinal pain. The patient reports that his symptoms started approximately 10 days ago after he helped a friend put up fencing in his yard. He describes the pain as a stretching sensation in his bilateral inguinal regions that has progressively worsened. He additionally reports weakness of the lower extremities, worse on the right compared to the left, which he attributes to be secondary to this pain. He denies associated numbness or tingling, and has no saddle anesthesia, bowel or bladder incontinence, fevers, chills, or back pain. He complains of dysuria, described as a burning sensation, which has occurred for the past four days. He has no constipation, diarrhea, shortness of breath, or chest pain. The patient had to be lifted out of his car and brought into the emergency department on a stretcher due to inability to bear weight on his lower extremities secondary to severe pain.

Past Medical History

Intravenous drug use

Past Surgical History

None

Medications

None

Allergies

Pencillin (hives)

Social History

Intravenous heroin one hour prior to arrival
Smoked marijuana, unspecified frequency of use
Patient denied alcohol use. He smoked 1 pack per day of cigarettes.

Physical exam



T: 99.7 F



HR: 120



BP: 155/90



RR: 24

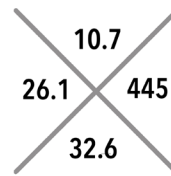


SpO2: 97% on RA

The patient is ill-appearing, but alert and in no acute distress. His HEENT exam is unremarkable. Cardiovascular exam demonstrates strong distal pulses and tachycardia. He is in no respiratory distress and had normal breath sounds. His abdomen is soft and nondistended without tenderness or guarding. No hernias are appreciated in the inguinal region. Neurologic exam demonstrates a normal cranial nerve exam, with intact sensation to light touch in all four extremities. Motor exam demonstrates weakness of hip

flexion, more pronounced on the right compared to the left (felt to be secondary to pain). Plantar flexion and extension is intact and equal bilaterally. He is unable to bear weight for gait testing secondary to pain.

Diagnostics



134	93	18	123
4.2	27	0.93	

Lactate 1.0
CRP 247
ESR 80

UA: Unremarkable

Blood cultures + methicillin-sensitive staphylococcus aureus (MSSA)
EKG: Sinus tachycardia, normal axis and intervals, no ST segment or T wave changes.

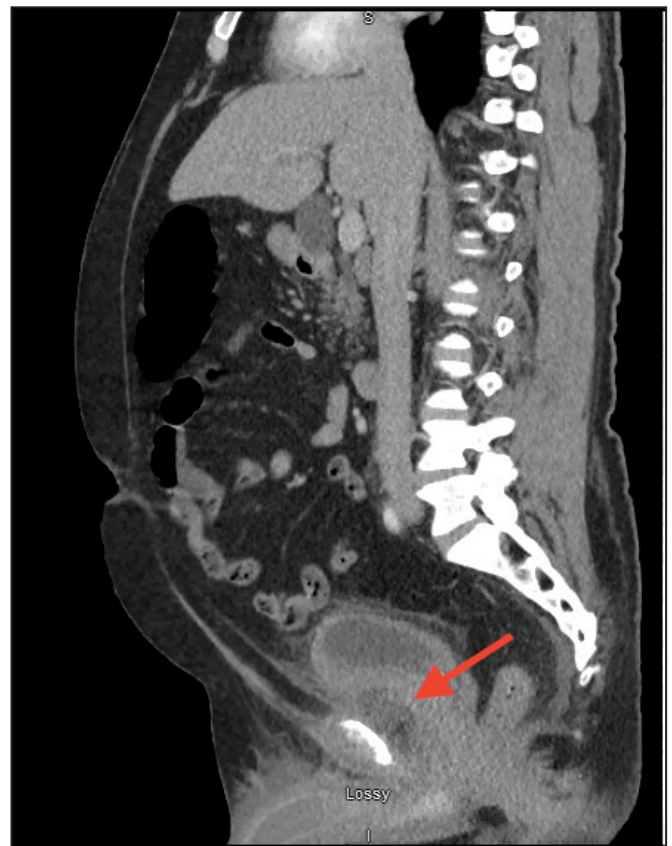

Image 5: Sagittal CT image of enhancing fluid collection with adjacent fat stranding anterior to the bladder

Hospital Course

The patient's history of IVDU, tachycardia, leukocytosis, and elevated inflammatory markers (ESR, CRP) with severe inguinal pain and dysuria were concerning for a pelvic or intra-abdominal infection. This was confirmed by CT, as the CT demonstrated a retropubic abscess secondary to septic arthritis of the pubic symphysis (see Image 1). The patient was started on vancomycin and ceftriaxone after blood cultures were drawn, and the orthopedics service was consulted for management. They recommended admission and interventional radiology consultation to percutaneously drain the extraperitoneal fluid collection. Unfortunately, the patient reported he had four children to care for at home and elected to leave against medical advice. He was ultimately discharged against medical advice with prescriptions for bactrim and keflex, and reported he would return to the emergency department when able. He did not return and was lost to follow-up.

Discussion

Pathophysiology

The space of Retzius is bordered externally by the transversalis fascia and internally by the parietal peritoneum of the abdomen. It is also known as the prevesical space, as it lies anterior to the urinary bladder, or the retropubic space, with its position posterior to the pubic symphysis. It is considered to be an extraperitoneal space and normally contains fat and blood vessels. Abscess formation in this site is relatively rare, but has been described in the literature through various case reports.^{1,2,3} As seen in the case described in this article, abscess formation can arise from septic arthritis or osteomyelitis of the pubic symphysis due to its adjacent contact with this space. Inflammation and infection of the pubic symphysis can arise from repetitive trauma, urologic or gynecologic surgery, urachal infections, or pregnancy.⁴ Other pelvic infections, such as perianal abscesses or Fournier's gangrene, can spread into the space of Retzius and cause infection.⁵ IVDU and immunosuppression may promote hematogenous spread and seeding of fibrocartilaginous joints like the pubic symphysis. The bacterial etiology of the abscess often depends on the associated inciting infection. For example, pubic symphysis osteomyelitis causing a retropubic abscess in a patient who uses drugs intravenously would be more likely to be secondary to a bacterium such as staphylococcus (as in this case), whereas a Fournier's gangrene spreading to the prevesical space would likely be polymicrobial to include gram-negative anaerobes.

Clinical Presentation

The patient typically presents with pubic or groin pain, although the symptoms may be vague, insidious, and difficult to discern. The pain may progress to be severe enough to impact ambulation and normal gait. Strength testing can be impaired secondary to

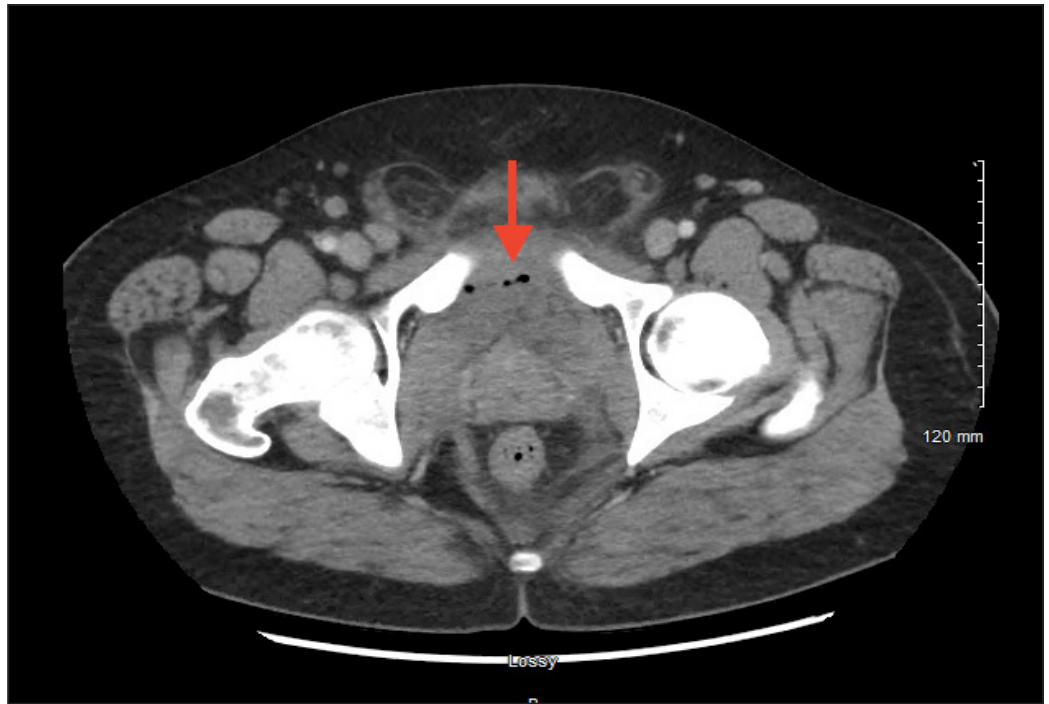

Image 6: Approximately 5 cm fluid and gas collection on axial CT in the prevesicular Space of Retzius

pain, particularly in the hip adductors and flexors.⁶ Dysuria, increased urinary frequency, and a sensation of incomplete bladder emptying may be experienced by the patient due to mechanical pressure on the bladder or its outlet from the adjacent abscess in the prevesical space.³ Systemic symptoms such as malaise, fevers, and chills can occur, especially with hematogenous infection. The pubic symphysis and suprapubic area are typically tender to palpation. Bowel function is usually normal.

Diagnostic Evaluation

Laboratory evaluation is typically consistent with infection, with leukocytosis and neutrophilia found on CBC. Thrombocytosis may indicate ongoing inflammation as an acute phase reactant. Other nonspecific markers of inflammation such as erythrocyte sedimentation rate (ESR) or C-reactive protein (CRP) may be elevated in response to this bacterial infection. C-reactive protein is a protein released by the liver that binds to dead or dying bacteria to trigger the complement system; its elevation, while nonspecific, suggests an ongoing bacterial infection.⁷ Similarly, erythrocyte sedimentation rate, which is the measure of how fast red blood cells (RBCs) fall to the bottom of a tube in a sample of blood, is typically elevated in infection due to increased inflammatory proteins in the blood, such as fibrinogen. These inflammatory proteins cause the RBCs to clump together and fall at a faster rate, thereby increasing the ESR. Urinalysis typically does not suggest infection, as the urinary symptoms are caused by mechanical compression as opposed to acute cystitis.

The test of choice for diagnosis of abscess in the space of Retzius in the ED is a CT of the abdomen and pelvis with IV contrast. This will also assist with evaluation of septic arthritis or osteomyelitis of the pubic symphysis and will evaluate for other intra-abdominal abscesses or fluid collections. MRI is another potential diagnostic modality to evaluate for osteomyelitis and adjacent abscess, a



Summer Penile Syndrome



Laura Frankenfeld,
University of Cincinnati R2

History of Present Illness

The patient is an eight-year-old male who presents with penile swelling that began after he was playing outside earlier that day. The patient reported to his mother that he was “bitten” by a bug in his groin. His mother noted a small bite mark over the shaft on the left side of the penis. The swelling increased over the shaft of the penis, involving the proximal aspect of the glans. The patient denies fever, pain over the areas of swelling, inability to void, dysuria, hematuria, scrotal swelling, testicular pain, or preceding trauma to the groin. He denies any other rash or bites on the body. The patient’s mother denies any new clothing, soaps, or detergent exposures. There are no pets in the home or recent contact with new animals.

Past Medical History

None

Past Surgical History

None

Medications

None

Allergies

No known medication allergies

Physical Exam



T 97.8 F°



HR 92



BP 120/94



RR 22

The patient is a well-appearing male around his stated age. The patient has a normal cardiopulmonary exam. Abdominal exam is unremarkable, without signs of tenderness, rigidity, rebound, or guarding. He has no rashes on skin exam. On genitourinary exam, the patient is

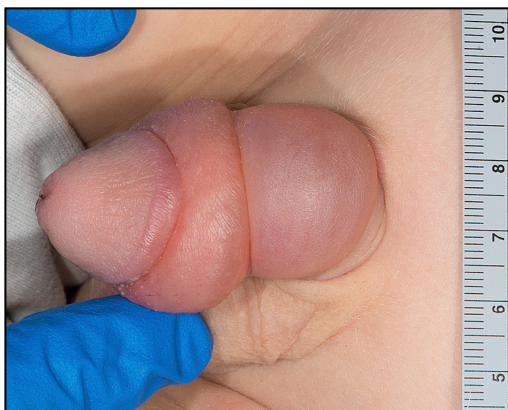

Image 7: Representative image of patient's genitourinary exam

noted to be circumcised. He has an erythematous area of swelling over the left shaft of the penis, as well as circumferential swelling around the base of the glans. The distal glans appears well perfused, and patient reports intact sensation over the entire penis and glans. No urethral discharge, ulcerations, or lesions are noted in the groin. The testicles have a normal lie without evidence of scrotal swelling, erythema, or tenderness. There are no signs of physical trauma and or lower extremity edema. The patient’s exam is otherwise unremarkable. A representative image of the patient’s penile swelling is included.

Emergency Department Course

The differential diagnosis in this case was wide and included Summer Penile Syndrome, scabies, bed bugs, balanoposthitis, cellulitis or abscess, protein deficient state or testicular torsion. Additional considerations included scabies and bed bugs, although he lacked the linear bites or additional cutaneous manifestations of these bites. He had no evidence of balanoposthitis, and perfusion distal to the swelling appeared intact such that he did not require immediate interventions such as aspiration. If he were uncircumcised, paraphimosis would also need to be excluded. The swelling and erythema were poorly circumscribed and nontender, making cellulitis or localized abscess unlikely. The patient had no evidence of diffuse swelling or anasarca that would raise concern for proteinuria or additional protein deficient states. His presentation was most consistent with Summer Penile Syndrome, a hypersensitivity reaction from Trombiculid mite or “chigger” bites. Summer Penile Syndrome does not result in any vascular compromise distal to the area of swelling. The patient was provided with Zyrtec for symptomatic relief and cold compresses to the penis in the emergency department. He voided in the emergency department spontaneously and without gross hematuria before discharge.

Discussion

Clinical Presentation

Summer Penile Syndrome, also known as Lion Mane’s Penis, is a pediatric hypersensitivity reaction to the Trombiculid mite, more commonly known as “chiggers,” “berry bugs,” and “red bugs.”¹ The disease presents with swelling at the base of the glans as well as unilateral or bilateral edema along the shaft of the penis. The larval form is the only parasitic stage of the Trombiculid life cycle, as nymphs and adults feed on other small insects in the environment. Trombiculid mites mature into their larval forms during the summer months in the Northern hemisphere, accounting for their seasonal proclivity in these geographic areas.² Bites occur primarily related to outdoor exposure such as grassy fields, gardens, or moist areas of soil. Eggs are on low-lying plants approximately one foot to the ground and lower.³ The bites appear as grouped, erythematous papules found in areas of tight-fitting clothing including underwear lines, sock lines, and waistlines. The papules can sometimes progress to more severe dermatologic complications including erythema and

cellulitis secondary to excoriations, and bullae. The erythema and swelling associated with these bites is related to the mite saliva causing epidermal liquefaction of the host along with host immune response.² The exact mechanism underlying the hypersensitivity groin reaction in certain patients is not entirely understood but is predominantly seen in the pediatric population.

The pruritis classically associated with chigger bites typically occurs three to six hours after the initial bite and during the release of larval enzymes.⁴ Often the heads of the larvae can be retained in the papule, leading to further inflammation in this area. In pediatric patients with the hypersensitivity reaction in the groin, a cutaneous lesion may not be readily identified, with one case report indicating identifiable lesions noted in only 56% of patients with the diagnosis. Dysuria is also reported in one third of patients, although not noted in the patient discussed.⁵

Treatment and Prevention

Summer Penile Syndrome resolves spontaneously with supportive care. The pruritus typically persists for three days, while the lesions may subside after one to two weeks. Penile swelling typically lasts for three days, although duration can be shorter or longer, with some studies indicating swelling up to 18 days.⁵ Oral and topical corticosteroids, systemic antihistamines, and cold compresses are the mainstay of therapies. Additional methods of covering the bites with topical sealants such as clear nail polish or collodion have not been proven to be effective measures.

Prevention of Summer Penile Syndrome is somewhat difficult, as this entails preventing exposures to Trombiculid-invested environments. Preventative measures include wearing topical insecticides and permethrin-infused clothing.³ Complications include superimposed cellulitis and abscess formation, typically from patient-induced excoriations. In North America, larval mites are not known for spreading disease. However, in certain areas of the world such as Southeast Asia, Indonesia, and Japan, Trombiculid larvae are vectors for a disease called Scrub typhus. This is caused by the bacterium *Orientia tsutsugamushi* and is marked by a small, black lesion at the bite site along with systemic symptoms of fever, malaise, mental status changes, and lymphadenopathy. Treatment in those cases is with doxycycline.⁶

Summary

Summer Penile Syndrome, a hypersensitivity reaction of the penis to the Trombiculid mite, is commonly seen in the pediatric population. There is limited data regarding the epidemiology; however, preventative measures can be taken including utilizing insecticides and specialized clothing. The symptoms typically occur three to six hours after the initial bite and resolve spontaneously with supportive care. Other etiologies should be considered when a patient presents with Summer Penile Syndrome as this can mask serious pathology such as protein deficient states, paraphimosis, and cellulitis.



Image 8: "Leptotrombidium, chigger mites" by Michael Wunderli is licensed with CC BY 2.0. Copy of license: <https://creativecommons.org/licenses/by/2.0/>

References

1. Sobolewski, et al. "Briefs: It's a Private Matter..." PEMBlog, 14 Dec. 2016, pencincinnati.com/blog/briefs-its-a-private-matter/.
2. Alexander, Lucas. "Chigger Bites." StatPearls [Internet]. U.S. National Library of Medicine, 29 June 2020, www.ncbi.nlm.nih.gov/books/NBK538528/.
3. DM, Hohenberger ME, Elston. "What's Eating You? Chiggers." Cutis, U.S. National Library of Medicine, June 2017, pubmed.ncbi.nlm.nih.gov/28686755/.
4. "Chapter 297: Mites, Including Chiggers." Mandell, Douglas, and Bennett's Principles and Practice of Infectious Diseases, Eighth Edition, by James Diaz, Saunders, 2015, pp. 3260-3260.
5. Smith GA, Sharma V, Knapp JE, Shields BJ. The summer penile syndrome: seasonal acute hypersensitivity reaction caused by chigger bites on the penis. *Pediatr Emerg Care.* 1998 Apr;14(2):116-8. [PubMed]
6. "Scrub Typhus." Centers for Disease Control and Prevention, Centers for Disease Control and Prevention, 3 Oct. 2019, www.cdc.gov/typhus/scrub/index.html.

Lymphogranuloma venereum

Continued from page 7

with erythromycin 500 mg orally four times a day for 21 days. Azithromycin is also a consideration, but has been shown to be associated with more treatment failure.⁴ Additionally, fluctuant buboes should be aspirated, both for pain relief and for the prevention of rupture or chronic sinus formation. On the other hand, incision and drainage of these nodes is not recommended as it can significantly delay the healing process.

Summary

LGV is an emerging STI in the Western world, particularly in the MSM patient population. On presentation, many of these patients will be coinfecting with concomitant STIs and are commonly HIV-positive. Symptoms can be wide-ranging depending on the stage of disease, including genital lesions, rectal pain, and inguinal lymphadenopathy. The diagnostics for LGV are evolving, including NAAT of extragenital sites, specific LGV PCR genotyping, and serologies. Currently, an appropriate clinical context along with a urine NAAT positive for chlamydia is the most practical approach to diagnosis. Prompt treatment is imperative, not only to cure the infection but to prevent long-term irreversible inflammatory changes associated with the disease.

References

1. Ceovic R, Guljin SJ. Lymphogranuloma venereum: diagnostic and treatment challenges. *Infect Drug Resist.* 2015;8:39-47. [Published 2015 Mar 27. doi:10.2147/IDR.S57540]
2. Hardick J, Quinn N, Eshelman S, et al. The HPTN 061 Study Team Multi-site screening for lymphogranuloma venereum (LGV) in the USA. *Sex Transm Infect.* 2011;87(1):60-64.
3. Stamm WE. In: Sexually Transmitted Diseases. 4. Holmes KK, Sparling PF, Stamm WE, Piot P, Wasserheit JN, Corey L, Cohen MS, Watts DH, editor. The McGraw-Hill Companies; 2008. Lymphogranuloma venereum; pp. 595-605.
4. Khosropour CM, Dombrowski JC, Barbee LA, Manhart LE, Golden MR. Comparing azithromycin and doxycycline for the treatment of rectal chlamydial infection: a retrospective cohort study. *Sex Transm Dis.* 2014;41(2):79-85. doi:10.1097/OLQ.0000000000000888
5. European Centre for Disease Prevention and Control. Sexually transmitted infections in Europe 2013. Stockholm: ECDC; 2015. http://ecdc.europa.eu/en/publications/_layouts/forms/Publication_DispForm.aspx?List=4f55ad51-4aed-4d32-b960-af70113db-b90&ID=1373.
6. Papp JR, Schachter J, Gaydos C, et al. Recommendations for the laboratory-based detection of Chlamydia trachomatis and Neisseria gonorrhoeae—2014. *MMWR Recomm Rep.* 2014;63.
7. Workowski KA, Bolan GA; Centers for Disease Control and Prevention. Sexually transmitted diseases treatment guidelines, 2015 [published correction appears in *MMWR Recomm Rep.* 2015 Aug 28;64(33):924]. *MMWR Recomm Rep.* 2015;64(RR-03):1-137.
8. Rönn MM, Ward H. The association between lymphogranuloma venereum and HIV among men who have sex with men: systematic review and meta-analysis. *BMC Infect Dis.* 2011;11:70. Published 2011 Mar 18. doi:10.1186/1471-2334-11-70
9. Mohseni M, Sung S, Takov V. Chlamydia. [Updated 2020 Nov 18]. In: StatPearls [Internet]. Treasure Island (FL): StatPearls Publishing; 2020 Jan-. Available from: <https://www.ncbi.nlm.nih.gov/books/NBK537286/>

terminate evaluation, further investigation and involvement with

an obstetrician is needed. If a viable pregnancy has been excluded the uterus can be evacuated and the contents sent to pathology for final determination. This may be difficult in partial molar pregnancies, where a fetus may be present. If there is absence of fetal heartbeat, additional obstetrical testing may be performed to confirm the diagnosis. If a fetal heartbeat is present, or if the diagnosis is suspected in very early gestation- prior to when a heartbeat would be normally detected- serial ultrasounds and hCG monitoring is necessary to evaluate for the development (or lack thereof) of a viable IUP.

Management and Treatment

Initial treatment for patient's presenting with a molar pregnancy should start with addressing airway, breathing, and circulation and focus on emergent stabilization if indicated. Hemorrhagic shock, severe anemia, pre-eclampsia, and thyroid storm should be addressed as they would be in any other patient. For a review on the management of pre-eclampsia, please see our article on hypertension in pregnancy from our Spring 2020 issue. Definitive treatment mandates the removal of the atypical pregnancy either through dilation and curettage or hysterectomy. Additionally, patients who are RhD (-) should receive anti-D immunoglobulin.

Thyroid storm from any etiology is managed via a multifaceted approach that aims to block the effects of active thyroid hormones on target tissues, decrease production and release of thyroid hormone, and minimize peripheral conversion of T4 to the more active T3. Beta blockers are administered to protect the heart and treat symptoms caused by increased adrenergic tone. Propranolol is the drug of choice as it provides beta blockade and inhibits peripheral deiodinase, leading to decreased conversion of T4 to T3. Propranolol can be administered either oral ly(60-80 mg q4-6 Hours) or intravenously (IV, bolus of 1 mg over 10 minutes, then 1-3mg over 10 minutes q1-3 hours until tachycardia resolves). Esmolol is another option when beta 1 selectivity is needed (such as in a patient with asthma); however, it is considered the second line choice because it does not possess the beneficial deiodinase blocking ability of propranolol. Thionamides, such as propylthiouracil (PTU) and methimazole, prevent the synthesis of new thyroid hormone by inhibiting thyroid peroxidase. In acute thyroid storm, PTU is preferred over methimazole because in addition to blocking thyroid hormone synthesis, it also decreases peripheral T4 to T3 conversion. The combined mechanisms of PTU result in a three-fold decrease in T3 at 24 hours when compared to methimazole.

PTU should be given in a loading dose of 500-1000 mg, followed by 250 mg every 4 hours. When there is high concern for thyroid storm or impending thyroid storm, empiric treatment with propranolol and PTU should be started without waiting for confirmatory thyroid studies. Delay in treatment of thyroid storm can lead to heart failure and cardiovascular collapse, whereas a few doses of these medications are unlikely to cause significant harm in a euthyroid patient. Potassium iodide is administered to take advantage of the Wolff-Chaikoff effect, in which increased levels of iodide transiently leads to decreased production of thyroid hormone. Patients in thyroid storm may have abnormally functioning thyroid tissue which does not properly respond to feedback inhibition. In these patients, administration of potassium iodide can actually increase thyroid hormone production rather than inhibit it. This is known as the Jod-Basedow phenomenon. To protect against the possibility of iodide resulting in a surge of thyroid hormone production, the administration of potassium iodide should be delayed until at least 1 hour after the administration of PTU. Potassium iodide should be given at a dose of 250 mg PO every 6 hours. Glucocorticoids are another therapy employed in thyroid storm, and work by inhibiting the peripheral conversion of T4 to T3. Hydrocortisone should be administered as a loading dose of 300 mg IV, followed by 100mg IV every 8 hours. Severe cases of thyroid storm, including those caused by molar pregnancy, which are unresponsive to the above therapies may be treated with plasmapheresis.²⁴⁻²⁵ Plasmapheresis removes circulating thyroid hormones from the body and allows for rapid control in thyrotoxicosis.²⁸ Regardless of the severity of the hyperthyroidism, patients who are experiencing clinical hyperthyroidism secondary to a molar pregnancy require beta blockade before they proceed to the OR as this could otherwise trigger thyroid storm.

As mentioned earlier, definitive treatment requires removal of the molar pregnancy. Following removal, it is crucial that patients are followed with serial hCG testing to monitor for the development of gestational trophoblastic neoplasia. Persistent elevations in hCG following removal of a molar pregnancy raise concern for the development of gestational trophoblastic neoplastic (GTN) disorders. These include invasive moles, choriocarcinoma, and placental site trophoblastic tumors. The International Federation of Gynecology and Obstetrics recommends repeat hCG testing every 1-2 weeks until it returns to normal since progression to GTN is rare after the hCG has returned to normal. After the initial normal hCG, serial testing may be discontinued after two normal hCGs one month apart following a partial mole, and seven normal hCGs, each one month apart, following complete moles.³¹ Women should also be on contraceptives during the surveillance period to prevent conception during that time, as pregnancy would make surveillance hCG testing meaningless. Oral hormone-based contraceptives are safe to use in this setting and have

Treatment of Thyroid Storm		
Therapy	Initial dose	Subsequent dosing
Beta-blockers • Propranolol (1st line)	60-80 mg PO 1 mg IV over 10 min	60-80 mg PO q4hr 1-3 mg IV over 10 min q 1-3 hr
Thionamides • PTU (1st line) • Methimazole (2nd line)	500-1000 mg PO 20 mg PO	250 mg PO q 4 hr 20 mg PO q 4-6 hr
Iodide • Potassium Iodide • Lugol's solution	5 drop of 250 mg 10 drops or 62.5 mg	5 drops or 250 mg q 4-6 hrs 10 drops or 62.5 mg q 8 hrs
Glucocorticoids • Hydrocortisone	100 mg IV	100 mg IV q 8 hrs

Table 1: Treatment of thyroid storm

WHO Risk Factor Scoring	0	1	2	4
Age	< 40	> 40		
Antecedent pregnancy	Mole	Abortion	Term	
Interval from index pregnancy (months)	< 4	4-6	7-12	> 12
Pretreatment hCG in mIU/mL	<10 ³	10 ³ -10 ⁴	10 ⁴ -10 ⁵	> 10 ⁵
Largest tumor size including uterus in cm		3-4	≥5	
Site of metastases including uterus	Lung	Spleen, Kidney	GI tract	Brain, Liver
Number of metastases identified		1-4	5-8	> 8
Previous failed chemotherapy			Single drug	2 + drugs

Gestational Trophoblastic Neoplastic (GTN) Disease Treatment Based on WHO Risk Score	
Low Risk (WHO score 0-4)	Single drug chemotherapy with Methotrexate or Actinomycin D
'Low Risk +' (WHO score 5-6) or Low Risk + Choriocarcinoma	Can treat with Methotrexate or Actinomycin D but higher failure rate with single drug therapy, so low threshold for multi drug regimen (see high risk)
High Risk (WHO score 7-12)	Etoposide + Methotrexate + Actinomycin D + Cyclophosphamide + Vincristine (EMA-CO)
Ultra High Risk (WHO ≥ 13)	Etoposide + Cisplatin, then EMA-CO

Tables 2: WHO Risk Factor Scoring; Table 3: GTN treatment based on WOH risk score

not been shown to increase risk of progression to GTN.²⁵ Post molar

progression to GTN occurs in up to 20% of cases of complete moles, and up to 5% of partial moles.²⁶⁻²⁷ If GTN develops, treatment involves various chemotherapy regimens based on the patient's calculated risk score, based off the World Health Organization (WHO) scoring system (See tables 2 and 3).³¹

Summary

Hydatidiform moles are a disease process of the trophoblast that occur secondary to abnormal fertilization. These typically present with symptoms of early pregnancy and may be complicated by vaginal bleeding, hyperemesis, preeclampsia, and hyperthyroidism. Patients with a history of spontaneous abortion or prior molar pregnancy are at increased risk of molar pregnancy. Diagnosis is made based on clinical suspicion, elevated hCG, and pelvic ultrasound. When the results of these evaluations are indeterminate, serial evaluations and further testing are necessary. Management involves removal of the atypical pregnancy and addressing any secondary symptoms or concurrent clinical conditions such as thyrotoxicosis. Following removal, patients need to undergo surveillance for development of GTN with serial hCGs until it is no longer detectable. Patients in the surveillance window post molar pregnancy need to be on a reliable form of contraception, which may safely include hormone-based methods.

References

1. Attrash, H. K., Hogue, C. J., & Grimes, D. A. (1986). Epidemiology of hydatidiform mole during early gestation. *American journal of obstetrics and gynecology*, 154(4), 906-909.
2. Parazzini, F., Mangili, G. I. O. R. G. I. A., La, C. V., Negri, E., Boccione, L., & Fasoli, M. (1991). Risk factors for gestational trophoblastic disease: a separate analysis of complete and partial hydatidiform moles. *Obstetrics and gynecology*, 78(6), 1039-1045.
3. Parazzini, F., VECCHIA, C. L., & Pampallona, S. (1986). Parental age and risk of complete and partial hydatidiform mole. *BJOG: An International Journal of Obstetrics & Gynaecology*, 93(4), 582-585.
4. Sebire, N. J., Foskett, M., Fisher, R. A., Rees, H., Seckl, M., & Newlands, E. (2002). Risk of partial and complete hydatidiform molar pregnancy in relation to maternal age. *BJOG: An International Journal of Obstetrics & Gynaecology*, 109(1), 99-102.
5. Lurain, J. R. (2010). Gestational trophoblastic disease I: epidemiology, pathology, clinical presentation and diagnosis of gestational trophoblastic disease, and management of hydatidiform mole. *American journal of obstetrics and gynecology*, 203(6), 531-539.
6. BERKOWITZ, R. S., GOLDSTEIN, D. P., & BERNSTEIN, M. R. (1985). Natural history of partial molar pregnancy. *Obstetrics & Gynecology*, 66(5), 677-681.

7. Sun, S. Y., Melamed, A., Goldstein, D. P., Bernstein, M. R., Horowitz, N. S., Moron, A. E., ... & Berkowitz, R. S. (2015). Changing presentation of complete hydatidiform mole at the New England Trophoblastic Disease Center over the past three decades: does early diagnosis alter risk for gestational trophoblastic neoplasia? *Gynecologic oncology*, 138(1), 46-49.
8. Soto-Wright, V., Bernstein, M., Goldstein, D. P., & Berkowitz, R. S. (1995). The changing clinical presentation of complete molar pregnancy. *Obstetrics & Gynecology*, 86(5), 775-779.
9. Hou, J. L., Wan, X. R., Xiang, Y., Qi, Q. W., & Yang, X. Y. (2008). Changes of clinical features in hydatidiform mole: analysis of 113 cases. *The Journal of reproductive medicine*, 53(8), 629-633.
10. Walkington, L., Webster, J., Hancock, B. W., Everard, J., & Coleman, R. E. (2011). Hyperthyroidism and human chorionic gonadotrophin production in gestational trophoblastic disease. *British journal of cancer*, 104(11), 1665-1669.
11. Zhao, M., Yin, Y., Guo, F., Wang, J., Wang, K., & Chen, Q. (2013). Placental expression of VEGF is increased in pregnancies with hydatidiform mole: possible association with developing very early onset preeclampsia. *Early human development*, 89(8), 583-588.
12. Koga, K., Osuga, Y., Tajima, T., Hirota, Y., Igarashi, T., Fujii, T., ... & Taketani, Y. (2010). Elevated serum soluble fms-like tyrosine kinase 1 (sFlt1) level in women with hydatidiform mole. *Fertility and sterility*, 94(1), 305-308.
13. Maynard, S. E., & Karumanchi, S. A. (2011, January). Angiogenic factors and preeclampsia. *In Seminars in nephrology* (Vol. 31, No. 1, pp. 33-46). WB Saunders.
14. Genest, D. R., Laoborde, O., Berkowitz, R. S., Goldstein, D. P., Bernstein, M. R., & Lage, J. (1991). A clinicopathologic study of 153 cases of complete hydatidiform mole (1980-1990): histologic grade lacks prognostic significance. *Obstetrics & Gynecology*, 78(3), 402-409.
15. MENCZER, J., MODAN, M., & SERR, D. M. (1980). Prospective follow-up of patients with hydatidiform mole. *Obstetrics & Gynecology*, 55(3), 346-349.
16. Jones, W. B., & Laursen, N. H. (1975). Hydatidiform mole with coexistent fetus. *American Journal of Obstetrics and Gynecology*, 122(3), 267-272.
17. Vimercati, A., de Gennaro, A. C., Cobuzzi, L., Grasso, S., Abruzzese, M., Fascilla, F. D., ... & Selvaggi, L. (2013). Two cases of complete hydatidiform mole and coexistent live fetus. *Journal of prenatal medicine*, 7(1), 1.
18. Petignat, P., Senn, A., Hohlfeld, P., Blant, S. A., Laurini, R., & Germond, M. (2001). Molar pregnancy with a coexistent fetus after intracytoplasmic sperm injection. A case report. *The Journal of reproductive medicine*, 46(3), 270.
19. Ross, J. A., Unipan, A., Clarke, J., Magee, C., & Johns, J. (2018). Ultrasound diagnosis of molar pregnancy. *Ultrasound*, 26(3), 153-159.
20. Fowler, D. J., Lindsay, I., Seckl, M. J., & Sebire, N. J. (2006). Routine pre-evaluation ultrasound diagnosis of hydatidiform mole: experience of more than 1000 cases from a regional referral center. *Ultrasound in Obstetrics and Gynecology*, 27(1), 56-60.
21. Johns, J., Greenwald, N., Buckley, S., & Jauniaux, E. (2005). A prospective study of ultrasound screening for molar pregnancies in missed miscarriages. *Ultrasound in Obstetrics and Gynecology: The Official Journal of the International Society of Ultrasound in Obstetrics and Gynecology*, 25(5), 493-497.
22. Kirk, E., Papageorgiou, A. T., Condous, G., Bottomley, C., & Bourne, T. (2007). The accuracy of first trimester ultrasound in the diagnosis of hydatidiform mole. *Ultrasound in Obstetrics and Gynecology: The Official Journal of the International Society of Ultrasound in Obstetrics and Gynecology*, 29(1), 70-75.
23. Azezi, A., Bayraktaroglu, T., Topuz, S., & Kalayoglu-Besik, S. (2007). Hyperthyroidism in molar pregnancy: rapid preoperative preparation by plasmapheresis and complete improvement after evacuation. *Transfusion and apheresis science*, 36(1), 87-89.
24. Adali, E., Yildizhan, R., Kulusari, A., Kurdoglu, M., & Turan, N. (2009). The use of plasmapheresis for rapid hormonal control in severe hyperthyroidism caused by a partial molar pregnancy. *Archives of gynecology and obstetrics*, 279(4), 569-571.
25. Dantas, P. R. S., Maestá, I., Rezende Filho, J., Junior, J. A., Elias, K. M., Horowitz, N., ... & Berkowitz, R. S. (2017). Does hormonal contraception during molar pregnancy follow-up influence the risk and clinical aggressiveness of gestational trophoblastic neoplasia after controlling for risk factors? *Gynecologic Oncology*, 147(2), 364-370.
26. Feltmate, C. M., Growdon, W. B., Wolfberg, A. J., Goldstein, D. P., Genest, D. R., Chinchilla, M. E., ... & Berkowitz, R. S. (2006). Clinical characteristics of persistent gestational trophoblastic neoplasia after partial hydatidiform molar pregnancy. *The Journal of reproductive medicine*, 51(11), 902-906.
27. Lurain, J. R., Brewer, J. I., Torok, E. E., & Halpern, B. (1983). Natural history of hydatidiform mole after primary evacuation. *American journal of obstetrics and gynecology*, 145(5), 591-595.
28. Muller, C., Perrin, P., Fallier, B., Richter, S., & Chantrel, F. (2011). Role of plasma exchange in the thyroid storm. *Therapeutic Apheresis and Dialysis*, 15(6), 522-531.
29. Ottanelli, S., Simeone, S., Serena, C., Rambaldi, M. P., Villanucci, A., Tavella, K., ... & Mello, G. (2012). PP120. Hydatidiform mole as a cause of eclampsia in the first trimester: A case report. *Pregnancy Hypertension: An International Journal of Women's Cardiovascular Health*, 2(3), 304.
30. Ramsey, P. S., Van Winter, J. T., Gaffey, T. A., & Ramin, K. D. (1998). Eclampsia complicating hydatidiform molar pregnancy with a coexisting, viable fetus. A case report. *The Journal of reproductive medicine*, 43(5), 456.
31. Ngan, H. Y., Seckl, M. J., Berkowitz, R. S., Xiang, Y., Goffier, F., Sekharan, P. K., & Lurain, J. R. (2015). Update on the diagnosis and management of gestational trophoblastic disease. *International Journal of Gynecology & Obstetrics*, 131, S123-S126.

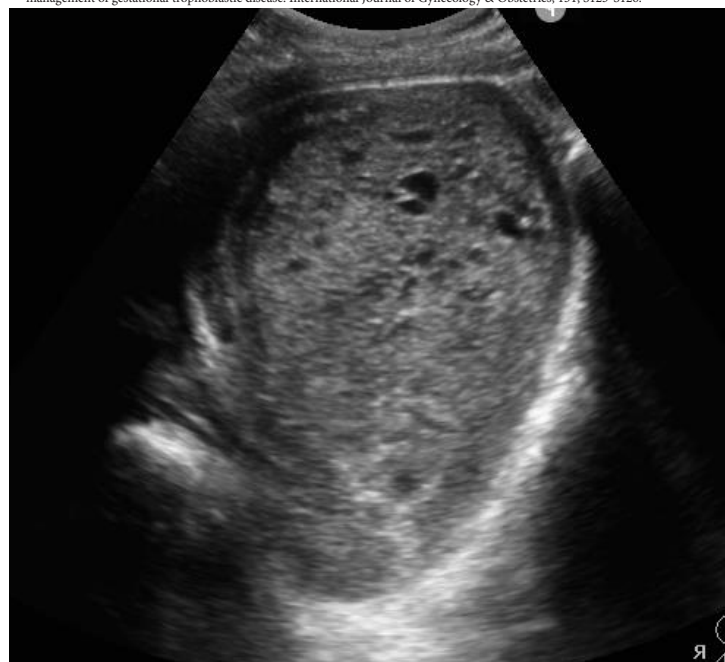

Image 9: Cross-sectional US of a uterus with 'snowstorm' pattern concerning for molar pregnancy

Hospital Course

The patient was given morphine, ondansetron, and intravenous fluids shortly after arrival to the emergency department. The providers were concerned about the patient's progression of symptoms, with differential outlined to include Fournier's gangrene, urinary tract infection, persistent epididymo-orchitis, testicular torsion, traumatic hematocele, incarcerated inguinal hernia, testicular cancer, and intra-abdominal infection with extension into the scrotum. Cross-sectional imaging and ultrasound was performed and demonstrated a heterogeneous fluid collection within the scrotal sac, consistent with a pyocele. Ceftriaxone was administered and urology was consulted. The patient was managed non-operatively, had improvement in his symptoms, and was discharged back to his skilled nursing facility with a two week course of ciprofloxacin.

Discussion

Pathophysiology and Epidemiology

Pyocele, an uncommon cause of testicular pain in the emergency department, is a purulent collection of fluid that forms between the parietal and visceral layers of the tunica vaginalis (see Figure 1).¹ Pyoceles most commonly occur as a complication of epididymitis or epididymo-orchitis, which develop from retrograde urinary tract infections. However, scrotal communication with the abdominal cavity can occur in the case of a patent processus vaginalis, and case reports exist of pyocele development as an extension of abdominal cavity infections, including perforated appendicitis and extension of spontaneous bacterial peritonitis.^{2,3} It is important to note that patent processus vaginalis is more common in newborn males, estimated to be present in 80-95% of all newborn males and declining to 15-37% after the first 2 years of life.⁴

In pyoceles secondary to epididymitis, the causative organisms vary with age. *Neisseria gonorrhoea* and *Chlamydia trachomatis* are more common in men younger than 35 years old, and *E. coli* are more common in individuals greater than 35 years old.⁵ Organisms in cases of trauma-related pyoceles typically result from seeding of dermatologic microbes into the scrotum from breakdown of the skin. These microbes can include *Enterococci*, *Streptococcus*, *Staphylococcus*, *Klebsiella*, and *Pseudomonas* species.

Clinical Presentation and Diagnosis

Examination will often reveal a tense, warm, swollen testicle related to the complex collection of fluid in between the layers of the

tunica vaginalis.⁶ In cases related to epididymitis, patients will often have an acute to subacute presentation marked by testicular pain (over the posterior aspect), swelling, penile discharge, and dysuria. An emergency provider should have a high index of suspicion for

conditions that may mimic a pyocele, including testicular abscess, torsion, and incarcerated inguinal hernias. Fournier's gangrene should also be considered if there are cutaneous manifestations or extensions beyond the scrotum.

Ultrasound is the preferred mode of diagnosis. A hydrocele appears as an anechoic collection in the tunica vaginalis on ultrasound examination. A pyocele appears as a complex fluid collection with septations, loculations, and air fluid levels on ultrasound examination. Doppler studies should also be obtained to

rule out concerns for torsion. An increase in Doppler signal may additionally be indicative of infectious process, as in this case. When the diagnosis is questionable or there is concern for tissue tracking, CT of the abdomen and pelvis may be warranted.

Management

Pyoceles require urgent urologic consultation. Management requires broad spectrum antibiotics, with at least a third-generation cephalosporin and metronidazole to cover gram negative and anaerobic organisms. Patients may require surgical drainage and possible orchiectomy if there is evidence of infarction.

Complications

Testicular abscess

Untreated epididymitis or epididymo-orchitis can result in a testicular abscess.⁵ This is an intra-testicular lesion and is therefore contained within the tunica albuginea. Disruption of the tunica albuginea can lead to communication with the tunica vaginalis and resultant formation of a scrotal abscess or pyocele.

Testicular infarction

Testicular infarct is a complication from epididymitis and pyoceles, typically caused by mass effect upon the spermatic cord with resultant venous and arterial insufficiency.⁷ An additional mechanism is thought to be related to arterial thrombosis from bacterial

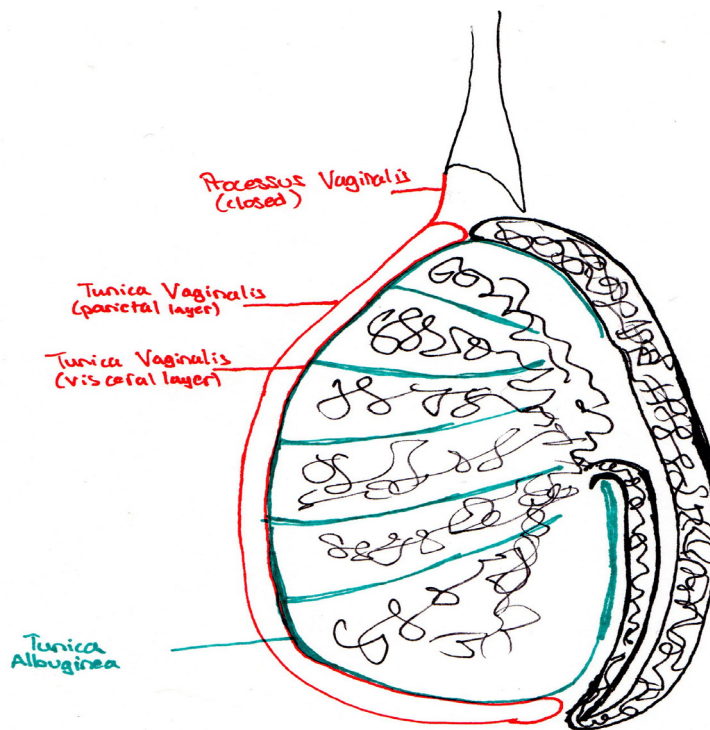


Figure 1. Testicular anatomy, Laura Frankenfeld, MD

	Risk factors	Physical exam	Septic?	Rapid progress?	Testicular involvement?	Treatment	High mortality?
Pyocele	Older age, bladder outlet obstruction, previous GU instrumentation, anal intercourse, unprotected intercourse, STI, epidymo-orchitis	Inflamed erythematous hemiscrotum with underlying tense, tender mass (caused by complex fluid collection between visceral and parietal tunica vaginalis)	Rare	Rare	Case reports requiring orchiectomy	Broad spectrum antibiotics and surgical drainage	Not reported
Fournier's Gangrene	Diabetes mellitus and alcohol use disorder, extremes of age, malignancy, chronic steroid use, cytotoxic drugs, lymphoproliferative diseases, malnutrition, HIV infection	Scrotal swelling and erythema, purulence, wound discharge, crepitation, fluctuance, progressing to extensive necrosis, fetid suppuration, gangrene	Yes	Yes	Rare	Hemodynamic support, broad spectrum antibiotics, multiple surgical debridements, intensive care	Yes

Table 4: Comparison of scrotal pyocele and Fournier's gangrene^{3,4,7}

endotoxins leading to decreased blood flow.^{8,9} Given that the testicle has little collateral flow, the testicle is susceptible to ischemia. Albeit

rare, testicular rupture is an additional complication from unrecognized epididymo-orchitis and testicular infarct.¹⁰

Fournier's Gangrene

Fournier's gangrene is a polymicrobial necrotizing fasciitis, with as many as 20-40% of cases attributable to genitourinary causes.^{11,12} Fournier's gangrene has a variety of presentations, all of which include an acute and progressive onset. Diabetics and immunocompromised individuals are at increased susceptibility.

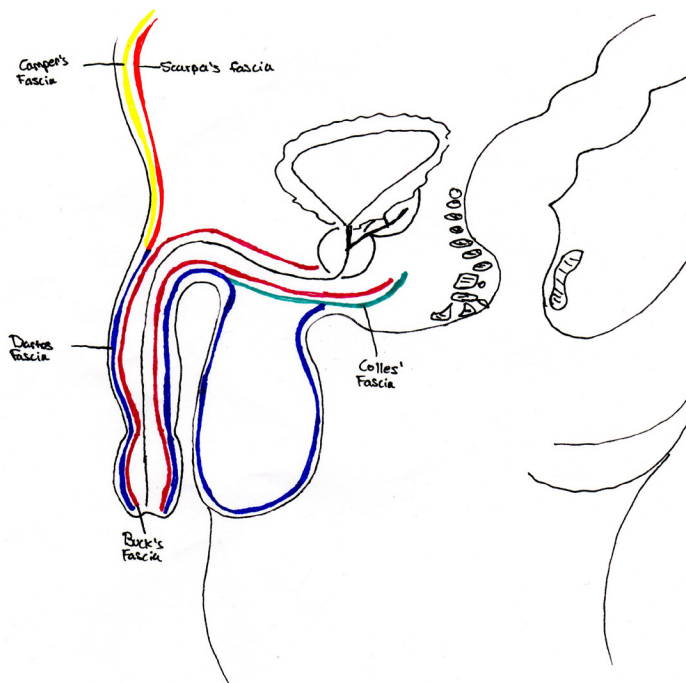


Figure 2. Pelvic anatomy and fascial planes, Laura Frankenfeld, MD

Anatomy of the fascial planes is important to understanding progression of infection (see Figure 2). Colles' fascia attaches at the perineal body and is continuous with Buck's fascia and Dartos' fascia, allowing for spread of infections along the anterior abdominal wall. Anorectal sources spread outward from the anal ridge, whereas genitourinary sources will more likely spread along Buck's and Dartos fascias. Ultrasound or CT examination may reveal the presence of subcutaneous emphysema in the perineum. This a true surgical emergency, requiring broad spectrum antibiotics and immediate surgical consultation for debridement. A comparison of Fournier's gangrene and pyocele is included in Table 1.

Summary

Scrotal pyoceles are rare but important considerations when presented with acute to subacute cases of scrotal pain. Management includes urologic evaluation, with antibiotics as a mainstay of therapy, although many progress to requiring surgical intervention. Ultrasound is helpful in confirming diagnosis and ruling out additional causes such as torsion, hematocele, and isolated abscesses. If the patient appears toxic, more advanced imaging such as CT scans may be needed to assess for Fournier's gangrene.

References

- Adhikari, Srikanth. "Small Parts-Testicular Ultrasound." *Testicular Ultrasound*, 2008, www.acep.org/sonoguide/smparts_testicular.html.
- Santucci, Richard A., et al. "Pyocele of the Scrotum: A Consequence of Spontaneous Bacterial Peritonitis." *The Journal of Urology*, July 1994, www.auajournals.org/doi/full/10.1016/S0022-5347%2801%2967706-1.
- Ramjith, Amit, et al. "Complete Testicular Infarction Secondary to Epididymo-orchitis and Pyocele." *Radiology Case Reports*, Elsevier, 12 Feb. 2020, www.sciencedirect.com/science/article/pii/S1930043320300017.
- Rahman, N, and K Lakhoo. Patent Processus Vaginalis: a Window to the Abdomen. *African Journal of Paediatric Surgery*, 2009, www.afripaedurg.org/.
- Avery, Laura L., et al. "Imaging of Penile and Scrotal Emergencies." *RadioGraphics*, 3 May 2013, pubs.rsna.org/doi/10.1148/rg.333125158.
- Bruner, D I, and J J Devlin. "Scrotal Pyocele: Uncommon Urologic Emergency." *Europe PMC, Journal of Emergencies, Shock, and Trauma*, Mar. 2012, europepmc.org/article/pmc/pmc3391854.
- LR. Delaney, B. Karmazyn, et al. "Pediatric Scrotal Ultrasound: Review and Update." *Pediatric Radiology*, Springer Berlin Heidelberg, 1 Jan. 1970, link.springer.com/article/10.1007/s00247-017-3923-9.
- Martin, Clyde Donald, et al. "More Than Just Torsion: An Unusual Case of Testicular Pain." *OUP Academic, Oxford University Press*, 28 Oct. 2019, academic.oup.com/milmed/article/185/5-6/e900/5607595.
- Farber, Nicholas J., et al. "Multidrug Resistant Epididymitis Progressing to Testicular Infarct and Orchiectomy." *Case Reports in Urology*, Hindawi, 27 Nov. 2013, www.hindawi.com/journals/criu/2013/645787/.
- Chia, Daniel, et al. "Testicular Infarction and Rupture: an Uncommon Complication of Epididymo-Orchitis." *Journal of Surgical Case Reports*, Oxford University Press, 10 May 2016, www.ncbi.nlm.nih.gov/pmc/articles/PMC4862172/.
- Drake, Tamsin. "Fournier's Gangrene." *Urology News*, 1 May 2015, www.urologynews.uk.com/features/features/post/fournier-s-gangrene.
- Thwaini, A, et al. "Fournier's Gangrene and Its Emergency Management." *Postgraduate Medical Journal*, BMJ Group, Aug. 2006, www.ncbi.nlm.nih.gov/pmc/articles/PMC2585703/.

lthough it is typically less available in the standard emergency department compared to CT.

Treatment

Percutaneous drainage of the abscess is the recommended approach for treatment.⁸ More invasive surgeries predispose the patient to further infections and complications. Blood cultures should be drawn, and the patient should be started on broad-spectrum antibiotics due to the multiple potential causes of this extraperitoneal infection. MRSA coverage should be present with an agent such as vancomycin, as hematogenous seeding of the pelvic bones can cause osteomyelitis with adjacent Space of Retzius abscess, as described in this case. This abscess can also be a result of contiguous spread of perirectal or perineal infection such as Fournier's gangrene; therefore, gram negative anaerobes should also be covered with an agent such as zosyn.⁹ In summary, recommended antibiotic regimens to cover suspected organisms would be vancomycin and zosyn or a combination of vancomycin, cefepime, and metronidazole. The patient may require a prolonged course of antibiotics if accompanying osteomyelitis is present.

Summary

The space of Retzius is located anterior to the bladder and posterior to the pubic symphysis. Abscesses can form in this extraperitoneal space, causing pelvic or inguinal pain, gait disturbance, urinary

symptoms, and constitutional symptoms in affected patients. Immunocompromise, IVDU, and other chronic conditions such as diabetes or end-stage renal disease may predispose patients to this infection, or it may occur spontaneously. Laboratory evaluation may be suggestive of active infection, with elevated inflammatory and infectious markers. A CT scan with IV contrast is preferred to diagnose this condition in the emergency department. IV antibiotics and percutaneous drainage are the primary treatment modalities. By understanding pelvic space anatomy and carrying a high index of suspicion for the disease, the emergency clinician can more accurately evaluate and diagnose extraperitoneal abscesses such as those in the space of Retzius.

References

1. Rising EH. Prevesical abscess. *Ann Surg.* 1908;48:224-36
2. Lorenzo, Gustavo Ph.D.; Meseguer, Maria A. M.D.; del Rio, Pedro M.D.; Sánchez, Juan Ph.D.; de Rafael, Luis M.D. Prevesical abscess secondary to pubis symphysis septic arthritis. *The Pediatric Infectious Disease Journal: September 2000 - Volume 19 - Issue 9 - p 896-898*
3. Pimentel torres J, Morais N, Cordeiro A, Lima E. Abscess originating from osteomyelitis as a cause of lower urinary tract symptoms (LUTS) and acute urinary retention. *BMJ Case Rep.* 2018;2018
4. Sexton DJ, Heskestad L, Lambeth WR, McCallum R, Levin LS, Corey R. Postoperative pubic osteomyelitis misdiagnosed as osteitis pubis: report of four cases and review. *Clin Infect Dis* 1993; 17: 695-700.
5. Oikonomou C, Alepas P, Gavriil S, et al. A Rare Case of Posterior Horseshoe Abscess Extending to Anterolateral Extraperitoneal Compartment: Anatomical and Technical Considerations. *Ann Coloproctol.* 2019;:216-220.
6. Choi H, McCartney M, Best TM. Treatment of osteitis pubis and osteomyelitis of the pubic symphysis in athletes: a systematic review. *Br J Sports Med.* 2011;45(1):57-64.
7. Paydar-Darian N, Kimia AA, Monuteaux MC, et al. C-reactive protein or erythrocyte sedimentation rate results reliably exclude invasive bacterial infections. *Am J Emerg Med.* 2019;37(8):1510-1515.
8. Sartelli M, Chichom-mefire A, Labricciosa FM, et al. The management of intra-abdominal infections from a global perspective: 2017 WSES guidelines for management of intra-abdominal infections. *World J Emerg Surg.* 2017;12:29.
9. Hamza E, Saeed MF, Salem A, Mazin I. Extraperitoneal abscess originating from an ischiorectal abscess. *BMJ Case Rep.* 2017;2017.

Annals of B Pod is always
looking
for interesting cases to publish!

Please submit cases via EPIC In-Basket message to Dr. Meaghan Frederick. Make sure to include the providers involved in the case

Submitted B Pod Cases

Epididymitis to pyocele	Frankenfeld/Goel
Molar pregnancy	Frederick/Goel
Lymphogranuloma venereum	Chuko/Palmer
Retzius abscess	Yates/Knight
Summer Penile Syndrome	Frankenfeld/Gray



ANNALS OF B POD

 University of
CINCINNATI Emergency Medicine